

CHANGES IN THE MORPHOLOGICAL PARAMETERS OF THE GASTRIC MUCOSA AND THE BASE OF THE GASTRIC MUCOSA OF WHITE RATS IN POLYPHARMACY

Toshmamatov B. N.

DJumanova N. E.

Samarkand State Medical Universities

Abstract:

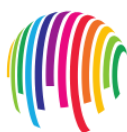In recent years, as a result of various exposures to harmful factors has led to changes in the chemical and physical properties of the gastric mucosa and morphological instability of the composition of the gastric mucosa. Inflammation and destructive damage to the mucous membrane of the gastrointestinal tract, which occurs against the background of taking nonsteroidal anti-inflammatory drugs, occupies one of the leading positions in medical practice. The problem of treating these diseases is a clear example of the complexity of managing mainly comorbid conditions. The conclusion is that when more than three types of anti-inflammatory drugs are used, as a result of their action, the size of the mucous layer of the gastric wall, the base of the mucous membrane is significantly reduced.

Key words: stomach, stomach wall, mucous membrane, polypharmacy, lymph, tissue.

Relevance studies in recent years have shown that 35% of the population suffers from gastritis and peptic ulcer disease. The study of organ-induced changes in the factors affecting the morphology of the gastric mucosa has been accelerating in recent years [20]. According to the scientific literature, the organs of the digestive system are inextricably linked with the external environment. Therefore, the mucous membrane of the organs of the digestive tract is affected by food. These effects occur in constant contact with the lymphoid tissue of the gastric mucosa and the subcutaneous base, which is the immune system [11, 12]. Long-term dry and solid nutrition has been shown to cause stable deviations in the morphogenetic structure of the gastric mucosa [13,19]. In recent years, as a result of various exposures to harmful factors has led to changes in the chemical and physical properties of the gastric mucosa and morphological instability of the composition of the gastric mucosa [10,23].

Inflammation and destructive damage to the mucous membrane of the gastrointestinal tract, which occurs against the background of taking nonsteroidal anti-inflammatory drugs, occupies one of the leading positions in medical practice. The problem of treating these diseases is a clear example of the complexity of managing mainly comorbid conditions. If we refer to the results of any clinical trials, the presence of comorbidity is often the exception criterion [14,21]. Some sources provide an acceptable definition of polypragmasia - the prescribing of more drugs (5 or more) than the clinical condition and quantitative determination - which is called polypragmass. In medical dictionaries, polypragmaa is also referred to as a "single prescription" kit. Most often, this phenomenon is observed in elderly patients [8,9].

Side effects of these groups of drugs are naturally associated primarily with damage to the mucous membrane of the gastrointestinal tract and the urinary system [2,3]. Thus, damage to the gastric mucosa resulting from long-term use of nonsteroidal anti-inflammatory drugs also leads to the development of lifethreatening conditions and a decrease in adaptive response [15,16,17]. The data presented show that currently the fight against polypragmass with anti-inflammatory drugs is one of the important tasks of medical care for patients of any age. This highlights the need to develop a strategy for the effective and safe use of drugs in the treatment of patients that improves the quality of care and reduces unwanted drug reactions [22,24,25]. The gastrointestinal tract is the most complex system of interpretation and interaction of the digestive organs. They are all inextricably linked. Disruption of a single body can lead to failure of the entire system. They all perform their functions and ensure the normal functioning of the body. All parts of the fracture are interrelated and pathological processes affect one of the sections [1,4,7]. However, due to the dynamics of structural changes of the gastric mucosa, the specific features of certain etiological factors can be considered as a typical pathological process (chronic inflammation) in a number of professions [5,6]. From the above, it is clear that the work done on studies of polypragmass and its effects on the gastrointestinal tract is insufficient. There are some inconsistencies between the available data, which require further morphological and morphometric investigations. The purpose of the study: The study of various effects of harmful factors lead to a change in the chemical, physical properties of the gastric mucosa



and morphological instability of the composition of the gastric mucosa. Materials and methods The experiment was performed in vivarium conditions in a total of 114 white non-breeding rats. Attention was paid to these storage conditions of rats at room temperature, in natural light and in ventilated, separate cages. In the early stages of the scientific experiments, all sexually mature rats were quarantined for seven days and transferred to the normal vivariate regimen after denial of somatic or infectious diseases. During the experiment, the physiological condition and behavior of the rats in the control group and the comparison group were carefully monitored. The following anti-inflammatory drugs were used to study the effect of polyfragmas in experimental groups of animals: Aspirin (NYaQD - salicylic acid derivatives), Paracetamol (NYaQD - anilide derivatives), Ibuprofen (NYaQD - propionic acid derivatives), Dexamethasone (synthetic antiinflammatory) effective anti-malarial agent).

Result and discussion

No significant change in body weight was observed in experimental rats compared with control group I, ie control animals, during the 150-day period of administration of nonspecific anti-inflammatory drugs (NAS) in different variants. Group III decreased by 3.8%, group IV by 6.1%, and our group V by 8.5% (Figure-1)

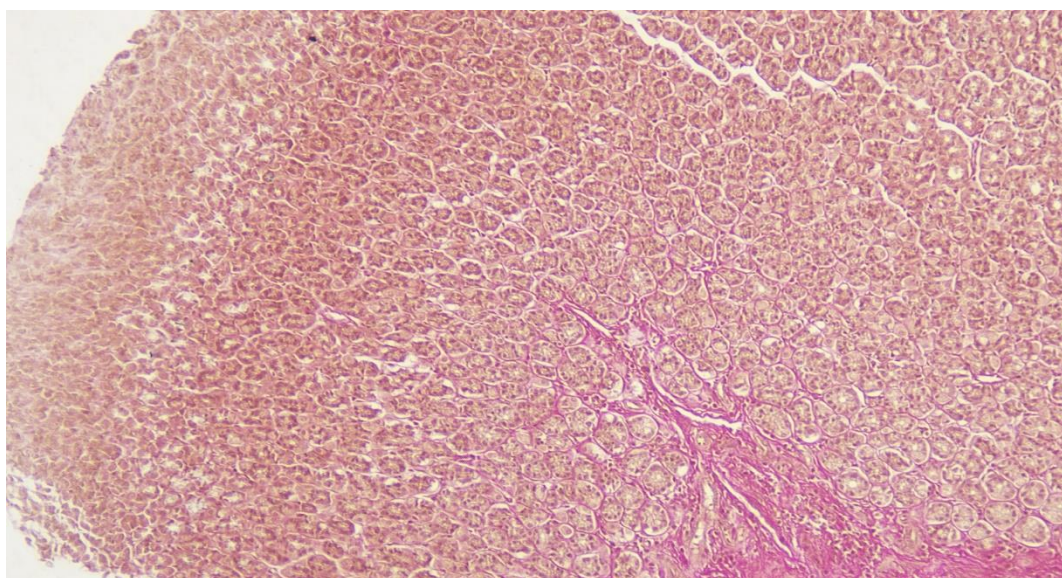


Figure 1. Changes in body weight (%) of white non-white rats over a period of 5 months under the influence of polypragmass.

The experiments revealed the homogeneity of the gastric mucosa layer, mucosal base and large and small curves of the stomach, and the best informative indicators were the total thickness of the gastric wall, mucosal layer thickness, mucosal base thickness, folds height, glandular tissue height, pit height between folds. The accuracy of the results and the degree of their recovery were found to depend on the intake of nonsteroidal anti-inflammatory drugs by laboratory animals. The morphometric parameters of the gastric wall of 5-month-old white rats in the experiment were as follows: the total thickness of the gastric wall increased from - 671.8 microns to -814.5 microns in the cardiac part, on average - 738.6 ± 15.41 microns; from -786.9 microns in the pyloric part -973 , Up to 1 μm , averaging - 832.4 ± 20.11 μm . The thickness of the mucous layer in the cardiac part ranged from - 434.3 μm to -512.1 μm , with an average of - 458.4 ± 8.40 μm ; in the pyloric region - 373.4 μm to -489.2 μm , with an average of - 443.4 ± 12.51 μm . The thickness of the submucosal base ranged from -39.6 μm to -45.79 μm in the cardiac region, averaging - 41.3 ± 0.66 μm ; in the pyloric region from -39.1 microns to -51.9 microns, with an average of - 46.8 ± 1.38 microns. The height of the glandular tissue located in the mucous layer ranged from -19.2 μm to -27.4 μm in the cardiac region, averaging - 23.4 ± 0.89 μm ; in the pyloric region -18.9 μm to -24.1 μm , with an average of - 20.3 ± 0.56 μm . When rats reach 5 months of age, the cardiac compartment contains glands containing $19.2 * 0.4$ head cells. In this case, the number of stem cells in the glands of the pyloric duct is $-21.4 * 0.7$, parietal cells - $15.1 * 0.6$ (Figure 2). Parietal gland cells in the neck and neck area are characterized by the presence of $-21.1 * 0.5$ in the cardiac part, pyloric duct glandular cells $-16.7 * 0.5$, mucus-producing glandular cells $-14.7*0.6$.



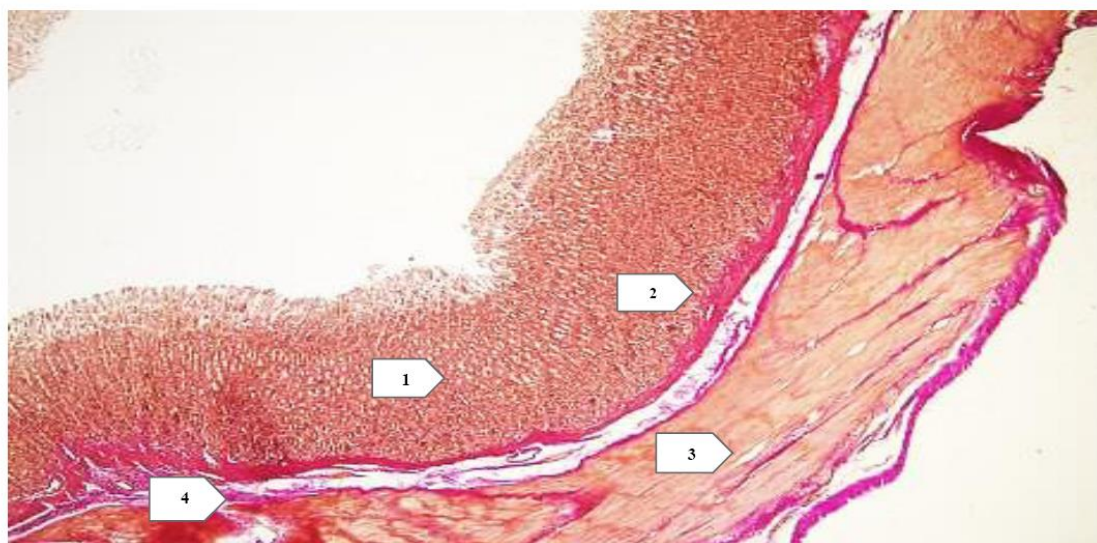


Figure 2. The structure of the stomach wall (body part) of 5-month-old rats. 1 - mucous membrane, 2 - submucosal base, 3 - muscular layer, 4 - glandular tissue of the mucous base. Stained with hematoxylin-eosin. Ok.10xob.4,0.

The body weight of 5-month-old white non-white rats under the influence of polypragmass ranged from -162 g to 241 g. to an average of 218.8 ± 8.22 gni. The gastric length of the 5-month-old rats in the experiment ranged from -34 mm to 35 mm. to, average -34.32 ± 0.22 mm. The width of the stomach ranged from -13 mm to -15 mm, with an average of -13.81 ± 0.22 mm.

Group I 5-month-old white rats under the influence of polypragmasia components of the cardiac, tubal, trunk and pyloric part of the stomach wall

Components of the stomach wall	Cardiac section (mkm)	depth (mkm)	body (mkm)	Pyloric section (mkm)
The total thickness of the stomach wall	671,8-814,5 738,6 \pm 15,41	622,3- 796,5 706,1 \pm 11,1 8	714,5- 803,7 768,6 \pm 16,1 2	786,9-973,1 832,4 \pm 20,11
The thickness of the mucous membrane	434,3-512,1 458,4 \pm 8,40	414,9- 500,9 441,4 \pm 7,15	401,3- 498,1 446,4 \pm 9,30	373,4-489,2 443,4 \pm 12,51
The height of the fold	426,5-503,1 441,3 \pm 8,27	436,5- 513,1 459,3 \pm 5,27	446,5- 529,1 486,3 \pm 5,97	364,5-461,6 410,1 \pm 10,49
Cloth tissue	19,2-27,4 23,4 \pm 0,89	17,2-27,4 21,4 \pm 0,28	18,2-31,4 24,4 \pm 0,75	18,9-24,1 20,3 \pm 0,56
The base of the mucous membrane	39,6-45,7 41,3 \pm 0,66	38,9-42,7 40,1 \pm 0,62	39,8-47,7 43,1 \pm 0,86	39,1-51,9 46,8 \pm 1,38

The thickness of the organ ranged from -12 mm to -13 mm and averaged -12.43 ± 0.22 mm. The length of the large curve ranged from -36 mm to -37 mm, with an average of -36.36 ± 0.11 mm. The length of the small curve ranged from -13 mm to -14 mm, with an average of -13.45 ± 0.11 mm. During this period, the total thickness of the gastric wall in the cardiac part of laboratory rats increased from -664.2 μ m to -758.1 μ m, on average - 719.8 \pm 10.14 μ m, and in the pyloric part - from -728.4 μ m to -856.3 μ m, on average - 786.3 \pm 13.81 microns

Components of the stomach wall	Cardiac section (mkm)	depth (mkm)	body (mkm)	Pyloric section (mkm)
The total thickness of the stomach wall	648,5-814,3 739,8 \pm 17,91	667,5- 845,3 779,2 \pm 14,6 1	688,3- 857,5 786,4 \pm 11,0 1	775,8-986,4 853,7 \pm 22,74
The thickness of the mucous membrane	426,9-532,5 478,7 \pm 11,40	436,9- 582,5 498,7 \pm 12,4 1	421,9- 554,5 495,7 \pm 15,0 7	365,2-498,5 439,1 \pm 14,40
The height of the fold	406,5-501,3 438,9 \pm 10,23	396,5- 485,2 441,9 \pm 9,28	401,5- 515,4 447,9 \pm 12,2 1	373,6-451,9 421,6 \pm 8,46
Cloth tissue	19,0-26,3 23,8 \pm 0,79	18,0-27,3 21,9 \pm 0,34	19,8-24,3 22,1 \pm 0,52	18,3-25,4 21,6 \pm 0,77
The base of the mucous membrane	32,3-40,9 35,8 \pm 0,93	31,1-39,9 34,8 \pm 0,53	32,9-42,2 37,7 \pm 0,82	38,8-53,7 46,8 \pm 1,61

Morphological and morphometric studies confirmed the visually determined patterns: the total wall thickness, fold height, mucosal layer, mucosal base, and glandular tissue height measurements in the 5-month experimental animals were 12.72%, 8.15%, and 18, respectively. , 37%, e, group 4 experimental rats decreased by 4.62%, 4.55% and 10.19%, group 3 animals decreased by 3.91%, 2.21% and 4.17% of the experiment, 2 In experimental rats, it was noted that the 1st group of the experiment was the same size as the experimental animals

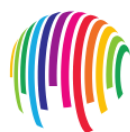Conclusion

Thus, the results obtained showed that when we inject different amounts of drugs into the body, there are different levels of morphological and morphometric changes in their effects on tissues and cells. The effects of anti-inflammatory drugs on gastric wall elements in white non-white rats have been studied experimentally. When more than three types of anti-inflammatory drugs were used, it was found that their effect was significantly reduced in the size of the mucous layer of the gastric wall, the base of the mucosa.



LIST OF REFERENCE

1. Алисейко Е. А., Громов И. Н. Влияние лития карбоната на морфологию лимфоидного аппарата органов пищеварения цыплят, вакцинированных против инфекционной бурсальной болезни // Актуальные проблемы интенсивного развития животноводства. - 2011. - №14 (2). - С. 101-107.
2. Аминова Г. Г., Григоренко Д. Е. Слизистая оболочка полых внутренних органов и ее роль в иммунных процессах // Актуальные проблемы гуманитарных и естественных наук. - 2012. - №8.
3. Беляева Е.В., Гущин Я.А. Методы визуализации и исследования кишечнораассоциированной лимфоидной ткани лабораторных животных // Лабораторные животные для научных исследований. - 2020. - №3. - С. 68-74.
4. Востроилова Г.А., Паршин П.А., Михайлов Е.В., Толкачев И.С., Хохлова Н.А., Чаплыгина Ю.А. Гисто-морфометрические показатели слизистой оболочки тонкого кишечника у поросят-гипотрофиков при применении Биферона-С и Аминоселеферона // Ветеринарный фармакологический вестник. - 2019. - № 2 (7). - С. 21-28.
5. Гладких Ф.В. Превентивно-лечебные стратегии фармакокоррекции гастропатии, индуцированной нестероидными противовоспалительными препаратами // Обзоры по клинической фармакологии и лекарственной терапии.-2017.-Т.15.-№4.-С.14-23.
6. Григоренко Д.Е., Васянина К.А. Лимфоидные структуры в стенке двенадцатиперстной кишки и в пейеровой бляшке подвздошной кишки крыс при моделировании гипокинезии //Клиническая и экспериментальная морфология. - 2013. - № 3 (15). - С. 47-51.
7. Гринь В.Г. Ангио архитектура пейеровых бляшек тонкой кишки белых крыс // Журнал ГрГМУ.- 2019.- №6. -С. 662-664.
8. Гусейнов Т.С, Гусейнова С.Т., Халилов М.А. Некоторые особенности макро и микроскопической анатомии структур стенки желудка крыс при воздействии сероводородных ванн //Вестник новых медицинских технологий. Электронное издание. - 2020. - №5. - С. 125-129.
9. Гусейнов Т.С., Гусейнова С.Т., Гасанова М.А., Кудаева П.Д. Морфология кишечнораассоциированной лимфоидной ткани при бальнеопроцедурах //



Известия вузов. Поволжский регион. Медицинские науки. 2017. - №3 (43). - С. 13-22.

10. Dzhumanova NE, Nazarova FS PROBABLE NEGATIVE IMPACT OF GENETICALLY MODIFIED PRODUCTS ON HUMAN HEALTH // Thematics Journal of Botany. - 2022. - T. 6. - No. 1.

11. Djumanova N.E. Maturation and Reproduction of African Catfish in Recirculated System in Uzbekistan Environments.// Texas Journal of Agriculture. – 2023. №1.p.1-3.

12. Nazarova F.Sh., Matkarimova G.M. Morpho - physiological and biochemical adaptations of helminthes.

13. Nazarova F.Sh., Khudoyberdieva G., Dzhumanova N.E. Biochemical comparative analysis of the ecological composition of phytonematodes.

14. Nazarova F. Sh., Dzhumanova N. E. Use of bentonite from the Azkamar deposit for balancing mineral nutrition // Academic research in the field of pedagogical sciences. - 2021. - Issue. 2. - No. 9. - C. 672-679.

15. Nazarova FS, Dzhumanova NE HAIR AND WOOL AS INDICATORS OF ENVIRONMENTAL POLLUTION BY MAN-MADE AND GEOCHEMICAL SOURCES // Thematics Journal of Microbiology. - 2022. - T. 6. - No. 1.

16 Nazarova F.S., Dzhumanova N.E. Hair and coat as indicators of environmental pollution by technogenic and geochemical sources // Thematic Journal of Microbiology. - 2022. - Issue. 6. - No. 1.

17. Nazarova F.S., Dzhumanova N.E., Tashmamatov B.N., Sh. O. Korzhavov. Ecological grouping of phytonematodes. Problems of biology and medicine. - 2020. No. 6. Volume 124. - C. 258-261.

18 Nazarova F.Sh., Dzhumanova N.E. Biological role of microelements and their content in epidermal formations. Economy and society. 1-2 (92). 2022. p. 94-103

19. Toshmamatov B.N. and coavt. Macroscopic structure of the ileocecal flap in rabbits // International Scientific and Practical Conference “World Science. - POCT, 2017. - C. 5. - No. 5. - C. 58-59.

20. Toshmamatov B.N. and coavt. Macroscopic structure of the ileocecal foramen of rats and rabbits in postnatal ontogenesis // International Scientific and Practical Conference “World Science. - POCT, 2018. - No. 3. - No. 5. - C. 53-54.



21. Toshmamatov B.N. Morphological changes in the stomach with polypharmacy
Home page of Science LLC Received 04/04/2021 Received 04/20/2021

22. Toshmamatov B.N., Teshaev Sh.J., Khudoyberdiev D.K. Consequences of polypharmacy with anti-inflammatory drugs on the morphology of the stomach wall
Problems of Biology and Medicine 2022, No. 1 (134) C.157-164

23. Toshmamatov B.N., Teshaev Sh. J., Khudoyberdiev D.K., Morphological structure of the gastric mucosa in polypharmacy with anti-inflammatory drugs 0, January 2022, pages 32-38

24. Toshmamatov B.N., Teshaev Sh. J. Changes in the morphological structure of the mucous membrane in polypharmacy. (2021). American Journal of Medical Sciences and Pharmaceutical Research, 3 (08), 51–57.

25. Toshmamatov B.N., Teshaev Sh.J., Khudoyberdiev D.K. Changes in the morphological parameters of the gastric mucosa and the base of the gastric mucosa of squirrels with polypharmacy. Problems of biology and medicine 6. 2022, №3 (136) C.190 -195

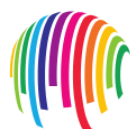26. Teshaev Sh.Zh., B.N. Toshmamatov Histological changes in the stomach during treatment with nosteroid drugs Problems of biology and medicine 2 (34) 2021 / S.260-264

27 Tashmamatov B.N. Morphometric parameters of the gastric mucosa in polypharmacy on anti-inflammatory drugs 9 (47) 2022. A new day in medicine. C.187-195

28. Toshmamatov BN et al. Macroscopic structure of the ileocecal valve in rabbits. //International Scientific and Practical Conference World science. - ROST, 2017. - Vol. 5. - No. 5. - S. 58-59.

29. Toshmamatov B. N. et al. Macroscopic structure of the ileocecal orifice in rabbits and rats in postnatal ontogenesis //International Scientific and Practical Conference World science. - ROST, 2018. - Vol. 3. - No. 5. - S. 53-54.

30. Тарасова Л. В., Трухан Д. И. Лекарственная безопасность в гастроэнтерологии // Экспериментальная и клиническая гастроэнтерология. - 2013. - №4. - С.81-86.



31. Трухан Д.И., Тарасова Л.В. Лекарственная безопасность и рациональная фармакотерапия в гастроэнтерологической практике // Клинические перспективы гастроэнтерологии, гепатологии. - 2013.- № 5.- С. 3-10.

32. Трухан Д.Н. Нестероидные противовоспалительные препараты сквозь призму коморбидности и лекарственной безопасности: в фокусе - амтолметин гуацил // Consilium Medicum. - 2015. - №2. - С.27-33.

33. Чичасова Н.В. Проблема оценки эффективности и безопасности нестероидных противовоспалительных препаратов // Современная ревматология. - 2016.- Т. 10, № 2.- С. 83-88.

34. Шекунова Е.В., Ковалева М.А., Макарова М.Н., Макаров В.Г. Выбор дозы препарата для доклинического исследования: межвидовой перенос доз // Вестник Научного центра экспертизы средств медицинского применения - 2020. - 10, No 1 - С. 19-28.

35. Шурыгина О.В. Репаративная регенерация тканей стенки влагалища половозрелых крыс при различных способах повреждения / О.В. Шурыгина // Морфологические ведомости. - 2008. - № 1-2. - С. 136-139.

36. Annuar Fazalda, Adam Quraishiah, Mohd Fahami Nur Azlina. Antiulcer Effect of Honey in Nonsteroidal Anti-Inflammatory Drugs Induced Gastric Ulcer Model in Rats: A Systematic Review // Evidence-Based Complementary and Alternative Medicine. - 2018.

37. Arthur J. Kastl, Natalie A. Terry, Gary D. Wu, Lindsey G. Albenberg. The Structure and Function of the Human Small Intestinal Microbiota: Current Understanding and Future Directions // Cellular and Molecular Gastroenterology and Hepatology. - 2019. - № 9(1). - P. 33-39.